



**PATIENT**

Skye Olson

**SPECIES**

Canine

**BREED**

Pitbull

**SEX**

Female Spayed

**AGE**

10 years

**WEIGHT**

68lbs

**PRESENTING CLINICAL SIGNS**

History: Grade 4/6 systolic heart murmur noted.

-Abnormal PE/Chem/CBC/UA Results: History of elevated liver enzymes and ProBNP. ProBNP previous 299, present 1456.

**RADIOGRAPHIC FINDINGS** \*NOTE: Images submitted for supplemental cardiac information only. Mild cardiomegaly. No obvious evidence of CHF.

**ELECTROCARDIOGRAPHIC FINDINGS** \*Note: Single lead ECGs are evaluated as a rhythm strip. Morphology/MEA cannot be definitively commented on.

A single lead ECG is available; 25mm/s, 10mm/mV. The average heart rate is 170bpm with a largely regular rhythm. P for every QRS complex and vice versa. The P and QRS morphologies are positive. Isolated VPCs are seen throughout; singles only, polymorphic. No couplets, triplets or runs appreciated. No supraventricular premature beats, pauses or other dysrhythmias observed. ECG diagnosis: Normal sinus tachycardia with isolated VPCs.

**ECHOCARDIOGRAM FINDINGS**

2D, m-mode, color flow and doppler imaging is available. Mild thickening of mitral valve leaflets (anterior>posterior) with no prolapse into the left atrial lumen. Moderate eccentric mitral regurgitation with moderate left atrial dilation. Elevated MR velocity. Mildly increased LV diameter with adequate myocardial function. The tricuspid valve appears mildly thickened with mild tricuspid regurgitation. Velocity consistent with early pulmonary hypertension. Mild right heart enlargement. The pulmonic and aortic valves are normal in morphology and mobility. Normal pulmonic and aortic outflow velocities. No aortic or pulmonic insufficiency. No pericardial or pleural effusion noted. No cardiac tumors observed.

**CARDIAC CHART**

**INTERPRETED BY**

Maggie Machen Lamy, DVM, DACVIM (Cardiology)

**IMAGING PERFORMED BY**

Kim Liedberg

**HOSPITAL NAME**

SVS Imaging WI

**REFERRING VET**

Dr. Stengel

**INVOICE**

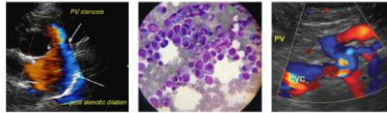
24790

**DATE**

6/14/22

CANINE CARDIAC PARAMETERS	MR VMAX (m/s)	TR VMAX (m/s)	LA/AO (Boon method)	LA/AO (Heart Base; Swe)	FS (%)	EF (%)	EPSS (cm)
NORMAL PARAMETER	4.5-5.5	<2.7	1.3	<1.6	28-40	40-100	<0.6
PATIENT	6.2	2.8	1.7	1.7	36	66	1.0
CANINE CARDIAC PARAMETERS	HR (BPM)	AV VMAX (m/s)	PV MAX (m/s)	BODY WEIGHT (kg)	LA 2D short axis Base view (cm)	LVIDd Avg; 2D and m-mode short axis (cm)	LVIDs Avg; 2D and m-mode short axis (cm)
NORMAL PARAMETER	50-100	0.7-1.7	0.7-1.6	BELOW	BELOW	BELOW	BELOW
PATIENT	140	1.8	1.0	30.8	3.6	5.2	3.3
*Normal chamber parameters expressed as a mean value (SD)				3	1.27 (5.3)	2.46 (2.46)	1.36 (5.5)
<b>BODY WEIGHT DEPENDENT PARAMETERS</b>				5	1.40 (4.5)	2.74 (5.2)	1.60 (4.7)
*Note: All measurements based upon multi-modal images and methods. An average value is reported.				10	1.50 (3.8)	3.27 (3.5)	2.06 (3.1)
				15	1.83 (2.0)	3.71 (2.4)	2.43 (2.1)
				20	2.02 (1.9)	4.14 (2.2)	2.80 (2.0)
				25	2.18 (2.4)	4.48 (2.9)	3.10 (2.5)
				30	2.33 (3.3)	4.83 (3.9)	3.39 (3.4)
				35	2.48 (4.3)	5.17 (5.0)	3.69 (4.5)
				40	2.62 (5.2)	5.48 (6.1)	3.96 (5.4)
				50	2.88 (7.1)	6.07 (8.3)	4.46 (7.4)

Adapted from June Boon, Veterinary Echocardiography, 1998  
Rishniw M and Hollis NE, J Vet Intern Med 2000; 14:429-435  
Hansson et al, Vet Rad and Ultrasound 2002  
Bonagura et al. Echocardiography: principles of interpretation, Vet Clin North Am 15:1177, 1995

**PATIENT**

Skye Olson

**SPECIES**

Canine

**BREED**

Pitbull

**SEX**

Female Spayed

**AGE**

10 years

**WEIGHT**

68lbs

**INTERPRETED BY**Maggie Machen Lamy,  
DVM, DACVIM  
(Cardiology)**IMAGING PERFORMED BY**

Kim Liedberg

**HOSPITAL NAME**

SVS Imaging WI

**REFERRING VET**

Dr. Stengel

**INVOICE**

24790

**DATE**

6/14/22

**INTERPRETATION OF THE FINDINGS & FURTHER RECOMMENDATIONS**

Chronic degenerative valve disease causing moderate mitral and mild tricuspid regurgitation. Moderate left atrial enlargement indicates there is relatively low risk for imminent complication, however risk for progression to spontaneous congestive heart failure in the future is elevated. Moderate pulmonary hypertension is identified, which should be monitored going forward. Finally, an elevated MR velocity is noted, and a baseline blood pressure is recommended. No additional issues are identified.

Based upon these findings and the results of the EPIC trial, Pimobendan is recommended as below. Prognosis is guarded at this stage (B2), with risk for progression going forward.

The ECG does confirm isolated ventricular premature contractions (VPCs), as the cause of the arrhythmia. VPCs are ectopic beats generated from abnormal conductive or fibrotic tissue in the ventricles of the heart muscle, and even frequent single VPCs will often cause no clinical signs in dogs. When sustained however, ventricular tachycardia can lead to symptoms such as lethargy and collapse.

VPCs are a very non-specific finding. They can be primary in origin such as ARVC, be secondary to significant cardiac disease, or be extra-cardiac in origin, i.e., due to pain, stress, inflammation, cancer, GI disease, DIC/sepsis, etc. In a dog with moderate structural disease, these may certainly be related; however, somewhat unusual in the absence of a crisis. Consider full systemic evaluation to rule out ancillary contributing issues. Unfortunately, there is always an elevated risk for collapse and sudden death in any arrhythmic patient, and even on medications this risk unfortunately still persists.

Based strictly on the amount of arrhythmia seen in hospital, low markers of malignancy (such as couplets), and a lack of associated clinical signs at home, no anti-arrhythmic treatment is clearly indicated. That being said, the only way to understand the true extent of the arrhythmia in the absence of stress and for an extended period of time is to apply a 24-hour holter monitor and this can be considered as a next step if desired. An alternative approach would be to utilize a holter monitor should the patient begin to experience clinical signs such as lethargy or collapse, however this is a less conservative approach. Discussion with the owner is advised.

Anesthetic risk is considered moderately elevated. Avoid ketamine, telazol, Dexdomitor (or other alpha-2 agonists) and acepromazine. Recommend having lidocaine CRI available for use in the event of worsening ventricular arrhythmias under anesthesia (CRI 50–75mcg/kg/min). Judicious IV fluid rates are advised to avoid fluid overload. A reasonable protocol includes opioid/benzodiazepine premedication, propofol induction, isoflurane maintenance.

Fish oil supplementation is recommended for dogs with arrhythmias (1000-2000mg of omega 3 and 6 once to twice daily).

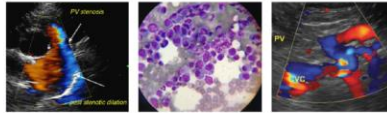
Monitor at home for collapse, exercise intolerance, and/or lethargy.

**PLAN**

Baseline BP. Administer Pimobendan 0.3mg/kg PO Q12h. Further systemic evaluation as discussed. Consider a holter monitor.

IMAGING PERFORMED BY

svsmobileimaging.com 309-737-3070



Clinical Sonography & Telectology

EDUCATIONAL TELECONSULTATION SERVICES™

1-800-838-4268 info@sonopath.com SonoPath.com

**PATIENT**

Recommend monitor for progression with a recheck echocardiogram and ECG in 6 months, sooner if any development of clinical signs.

Skye Olson

**IMAGES**

**SPECIES**

Canine

**BREED**

Pitbull

**SEX**

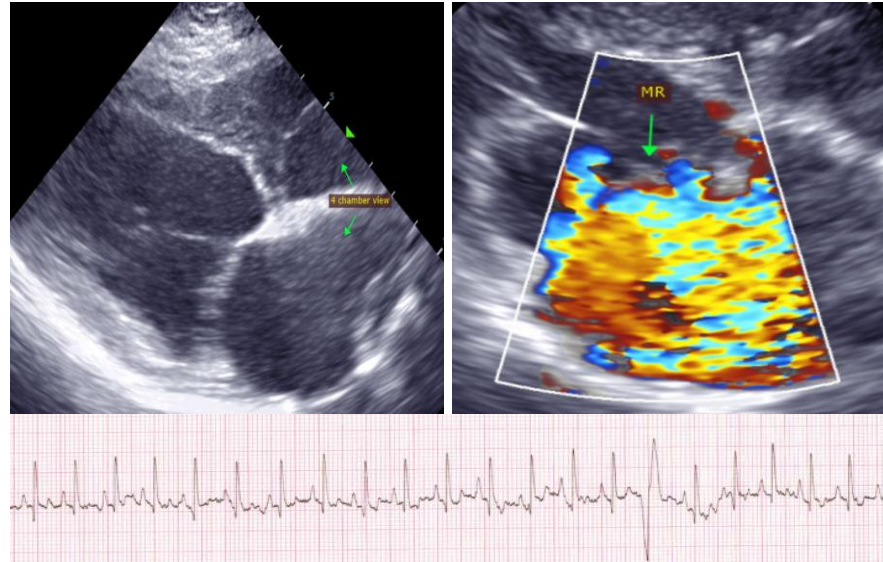
Female Spayed

**AGE**

10 years

**WEIGHT**

68lbs



The information and recommendations provided are based on the images presented by the referring veterinarian. No evaluation can be communicated regarding pathology that was not visible in the image/video clips provided.

Thank you for this referral. If the clinical or image interpretation does not parallel your findings or if I can be of any further assistance, please contact me.

**Maggie Machen Lamy, DVM**  
Diplomate of the American College of Veterinary Internal Medicine (Cardiology)  
info@sonopath.com

**INTERPRETED BY**

Maggie Machen Lamy,  
DVM, DACVIM  
(Cardiology)

**IMAGING PERFORMED BY**

Kim Liedberg

**HOSPITAL NAME**

SVS Imaging WI

**REFERRING VET**

Dr. Stengel

**INVOICE**

24790

**DATE**

6/14/22